

Neural Correlates of Exposure to Traumatic Pictures and Sound in Vietnam Combat Veterans with and without Posttraumatic Stress Disorder: A Positron Emission Tomography Study

J. Douglas Bremner, Lawrence H. Staib, Danny Kaloupek, Steven M. Southwick, Robert Soufer, and Dennis S. Charney

Background: *Patients with posttraumatic stress disorder (PTSD) show a reliable increase in PTSD symptoms and physiological reactivity following exposure to traumatic pictures and sounds. In this study neural correlates of exposure to traumatic pictures and sounds were measured in PTSD.*

Methods: *Positron emission tomography and $H^2[^{15}O]$ were used to measure cerebral blood flow during exposure to combat-related and neutral pictures and sounds in Vietnam combat veterans with and without PTSD.*

Results: *Exposure to traumatic material in PTSD (but not non-PTSD) subjects resulted in a decrease in blood flow in medial prefrontal cortex (area 25), an area postulated to play a role in emotion through inhibition of amygdala responsiveness. Non-PTSD subjects activated anterior cingulate (area 24) to a greater degree than PTSD patients. There were also differences in cerebral blood flow response in areas involved in memory and visuospatial processing (and by extension response to threat), including posterior cingulate (area 23), precentral (motor) and inferior parietal cortex, and lingual gyrus. There was a pattern of increases in PTSD and decreases in non-PTSD subjects in these areas.*

Conclusions: *The findings suggest that functional alterations in specific cortical and subcortical brain areas involved in memory, visuospatial processing, and emotion underlie the symptoms of patients with PTSD.* Biol Psychiatry 1999;45:806–816 © 1999 Society of Biological Psychiatry

Key Words: Positron emission tomography, memory, posttraumatic stress disorder, frontal cortex, cingulate, function

Introduction

Posttraumatic stress disorder (PTSD) is characterized by recurrent trauma-related memories, and increased fear responding and physiological reactivity to reminders of the trauma, coupled with sleep disturbances, nightmares, avoidance, increased startle, and other symptoms that can persist for many years after the original traumatic event (Pitman 1989; Bremner et al 1995a). The failure of extinction of fear responsiveness to “cues” related to the original trauma can be modeled in laboratory animals and is an important part of the clinical presentation of PTSD patients. Abnormal traumatic recall and fear responding, which can be reliably provoked with trauma-related pictures and sounds or traumatic scripts, are associated with an increase in physiological reactivity, including increased heart rate and blood pressure, in PTSD patients (Blanchard et al 1982; Malloy et al 1983; Pitman et al 1987; reviewed in Prins et al 1995).

Regulation of these peripheral markers of physiological responsiveness by cingulate and amygdala raises the possibility that alterations in function in these brain areas may be associated with PTSD symptoms. Early studies showing an increase in fear-related behaviors following removal of cerebral cortex in cats also led to the hypothesis that these areas, in addition to thalamus, hypothalamus, hippocampus, and adjacent cortex, regulate emotion and the stress response (MacLean 1949). These brain areas are functionally interrelated, and via pathways through the hypothalamus and medial prefrontal cortex (area 25) effect the peripheral stress response in increased heart rate, blood pressure, peripheral catecholamines, and cortisol (Vogt et al 1992; LeDoux 1993; Devinsky et al 1995).

Recently there has been an increased appreciation for the role that abnormalities in memory play in the present-

From the Department of Psychiatry (JDB, SMS, DSC) and Department of Diagnostic Radiology (JDB, LHS, RS), Yale University School of Medicine, New Haven, Connecticut; National Center for Posttraumatic Stress Disorder, New Haven, Connecticut (JDB, SMS, DSC); Yale/VA PET Center, New Haven, Connecticut (JDB, RS); Yale Psychiatric Institute, New Haven, Connecticut (JDB); VA Connecticut Healthcare Center, West Haven, Connecticut (JDB, SMS, RS, DSC); Boston VA Medical Center, Boston, Massachusetts (DK); and Department of Psychiatry, Boston University, Boston, Massachusetts (DK).

Address reprint requests to J. Douglas Bremner, MD, Yale Psychiatric Institute, POB 208038, Yale Station, New Haven, CT 06520.

Received December 12, 1997; revised August 4, 1998; accepted September 8, 1998.

tation of patients with PTSD. PTSD patients demonstrate deficits in verbal declarative memory, which are associated with a reduction in volume of the hippocampus, a brain area involved in learning and memory (Squire and Zola-Morgan 1991) (reviewed in Bremner et al 1995a). On the other hand, PTSD is characterized by intensification of nonverbal aspects of memory, including “hypermnemonic” visual memory traces related to traumatic events (Pitman et al 1993; Bremner et al 1996a). The excessive vigilance seen in PTSD may be associated with increased demands on brain areas involved in visuospatial aspects of memory function and in integration with evaluation of stimuli for potential threat and planning of response to stimuli. Based on this we have hypothesized that increased activity in cortical brain areas involved in memory and visuospatial processing, including prefrontal and parietal cortex (Bremner et al 1995a) (in addition to limbic areas), underlies the symptoms of PTSD. Medial prefrontal cortical areas also modulate fear responding through inhibitory connections with the amygdala that are involved in the fear response as well as through effecting peripheral sympathetic and hormonal responses to stress (Vogt et al 1992; LeDoux 1993; Devinsky et al 1995). We have hypothesized that dysfunction of these areas plays a role in failure of extinction to fear in PTSD (Bremner et al 1996a). A complete understanding of functional connections of cortical and subcortical brain areas involved in emotion and memory is important in constructing a model for neural correlates of PTSD.

Recent advances in neuroimaging technology have made it possible to study central brain correlates of PTSD. Reduced volume of the hippocampus measured with magnetic resonance imaging (MRI) was found in several populations of PTSD patients, possibly secondary to stress-induced atrophy (Bremner et al 1995b, 1997b; Gurvits et al 1996; Stein et al 1997). Decreased metabolism measured with positron emission tomography (PET) was found at baseline in temporal and prefrontal cortex in combat-related PTSD (Bremner et al 1997a) and in parietal cortex in patients with PTSD and comorbid substance dependence (Semple et al 1996).

Exposure of PTSD patients to traumatic scripts resulted in increased blood flow in limbic regions (right amygdala, insula, orbitofrontal cortex, and anterior cingulate), and decreased blood flow in middle temporal and left inferior frontal cortex, as measured with PET (Rauch et al 1996). This study did not involve a control group, however, so it is not possible to determine whether the changes are specific to PTSD. A second PET study that did utilize control subjects found increased blood flow in right amygdala and anterior cingulate, and decreased blood flow in middle temporal and left inferior frontal cortex in PTSD patients relative to control subjects during trauma-related

mental imagery (Shin et al 1997). Provocation of PTSD symptoms with the pharmacologic agent yohimbine (which stimulates brain norepinephrine release) resulted in a relative failure of orbitofrontal cortex activation in PTSD patients relative to control subjects, as well as differential functional responses to challenge in temporal, parietal, and prefrontal cortex. These findings were consistent with increased noradrenergic responsiveness to yohimbine in PTSD (Bremner et al 1997a).

The purpose of the present study was to use PET in the examination of neural correlates of exposure to traumatic pictures and sounds in Vietnam combat veterans with and without PTSD. Traumatic pictures and sounds represent a standardized and well-established paradigm for the provocation of PTSD symptoms that have several advantages over other techniques for induction of PTSD symptoms (Kaloupek and Bremner 1996; Prins et al 1995). They have ecological validity, resembling “traumatic cues” that patients encounter in their environment, complete with the complex interplay of visual and auditory stimuli. In addition, traumatic pictures and sounds (unlike individualized scripts) can be presented in an identical fashion to all subjects in a research study. We hypothesized that exposure to traumatic pictures and sounds would result in greater activation in cortical and subcortical brain areas implicated in memory, emotion, and the fear response, including amygdala, hippocampus and adjacent cortex, cingulate, and prefrontal and parietal cortex, in combat veterans with PTSD relative to those without PTSD. We further hypothesized a relative failure of activation in medial prefrontal cortical areas involved in modulation of fear responsiveness through inhibition of amygdala function.

Methods and Materials

Subjects in the study were Vietnam combat veterans with PTSD ($n = 10$) and comparison subjects, who were Vietnam combat veterans without PTSD ($n = 10$). Subjects were recruited through a VA Medical Center PTSD program and newspaper advertisement. To identify the subgroup of PTSD patients who are reactive to the types of traumatic stimuli used in this study (Blanchard et al 1982; Kaloupek and Bremner 1996; Malloy et al 1983; Pitman et al 1987; Prins et al 1995), subjects underwent a screening to determine emotional and psychophysiological reactivity. Subjects were determined to be reactive with a 5 beats per minute increase in heart rate and a 50 points increase in Subjective Units of Distress (SUDs) scale score (described below) for the combat slide presentation relative to neutral slide presentation. Out of 13 PTSD patients screened, 10 met criteria, while all of the non-PTSD veterans met these criteria.

Vietnam veterans were included in the PTSD group who: 1) were demonstrated to be reactive to combat slides and sounds using the psychophysiology screening procedure outlined above; and 2) met criteria for current combat-related PTSD as assessed

by the Structured Clinical Interview for DSM-IV (SCID) (Spitzer et al 1987). Vietnam veterans were included in the comparison group who did not meet these three criteria and did not have an Axis I psychiatric disorder based on the SCID. All subjects had combat exposure, which involved being in firefights (gun battles) with the enemy, being wounded, or seeing others killed or wounded. All subjects gave written informed consent for participation, were free of major medical illness on the basis of history and physical examination, lab testing, and electrocardiogram, were not actively abusing substances or alcohol (past 6 months), and were free of all medications for at least 4 weeks prior to the study. Subjects were not taken off of medication for the purposes of participating in the study.

Subjects were excluded with a serious medical or neurological illness, organic mental disorders or comorbid psychotic disorders, current alcohol and/or substance abuse or dependence (past 6 months), retained metal, a history of head trauma, loss of consciousness greater than 10 min, cerebral infectious disease, or dyslexia. There was no difference in age between the PTSD patients (mean = 47 years, SD = 3) and comparison subjects (mean = 50 years, SD = 3). Nine out of 10 of the PTSD patients were white, 1/10 black; 9/10 of the comparison subjects were white, 1/10 black. All of the subjects, both PTSD and comparison subjects, were male and right-handed.

Seven out of 10 PTSD patients (70%) fulfilled criteria for a lifetime history of major depression and 3 (30%) for current major depression based on the SCID interview. One patient (10%) met criteria for current dysthymia, and 1 (10%) for lifetime bipolar disorder. Two out of 10 (20%) patients fulfilled criteria for lifetime history of panic disorder with agoraphobia, and 1 (10%) for current panic disorder with agoraphobia; 1 (10%) met criteria for lifetime and current history of panic disorder without agoraphobia. One out of 10 (10%) fulfilled criteria for current agoraphobia without panic disorder, 2 (20%) for current social phobia, 2 (20%) for current simple phobia, 1 (10%) for current obsessive-compulsive disorder, and 1 (10%) for lifetime generalized anxiety disorder. Six patients (60%) fulfilled criteria for a lifetime history of alcohol dependence, and 1 (10%) for lifetime alcohol abuse. There were no patients with substance abuse or dependence other than alcohol.

Each subject underwent four scans on a single day. The subject was placed in the scanner with his head held in a holder to minimize motion and positioned with the canthomeatal line parallel to an external laser light. Electrocardiogram leads were attached to the chest in standard positions for measurement of heart rate and cardiovascular function, and a dinemap cuff was attached to the left arm for measurement of blood pressure. An intravenous line was inserted for administration of [^{15}O]H $_2\text{O}$. Following positioning within the camera gantry, a transmission scan of the head was obtained using an external $^{67}\text{Ga}/^{68}\text{Ge}$ rod source, to correct emission data for attenuation due to overlying bone and soft tissue. SUDs scale ratings (a visual analogue scale scored from 0 to 100 for the assessment of current subjective level of distress) were performed every 5 min until three successive ratings were unchanged, indicating that the subject had adapted to the study setting. Baseline subjective ratings were then collected, including a 17-item PTSD symptom scale (Southwick et al 1993), the Panic Attack Symptom Scale (PASS)

(Southwick et al 1993), Clinician Administered Dissociative States Scale (CADSS), a reliable and valid 27-item scale for the measurement of current dissociative states (Bremner et al 1998), another SUDs scale, and a visual analogue scale (scored from 0 to 100) for the assessment of fear (Southwick et al 1993). Subjects also underwent baseline measurement of heart rate and blood pressure.

Subjects then underwent scanning under neutral and traumatic (combat slide) conditions. No “resting” scans (i.e., scans in the absence of any stimulation) were performed, as there is evidence for an increase in frontal lobe activity in the absence of stimulation, which could interfere with the study results. A fixed order (two presentations of neutral slides and sounds followed by two presentations of combat slides and sounds) was used for all subjects, to prevent anxiety elicited by the combat slides from persisting into neutral slide presentations. Combat and neutral slides and sounds from an ongoing multisite VA Cooperative Study on the psychophysiology of PTSD were used for the presentation materials. Neutral slides were of winter scenes, with nonverbal music. Combat slides were actual photographs from Vietnam, and included scenes such as a male soldier throwing a hand grenade, a sniper in the bushes, and evacuation of wounded soldiers, accompanied by appropriate sounds, such as machine gun fire, the sound of the jungle, and of helicopters, respectively. Each scan condition involved four slides presented over a total of a 2-min period. One minute into the presentation subjects received a bolus injection of 30 mCi of [^{15}O]H $_2\text{O}$ immediately followed by a PET scan acquisition, which was 1 min in length. PET imaging was performed on a Posicam PET camera (Positron Corp) (in plane resolution after filtering, 6 mm full width at half maximum). Subjects then underwent measurement of heart rate and blood pressure, as well as behavioral ratings for the time of the presentation, including PASS, CADSS, SUDs, fear analogue, and PTSD Symptom Scale.

Images were reconstructed and analyzed on a SunSparc Workstation using statistical parametric mapping (spm95). Images for each patient set were realigned to the first scan of the study session. The mean concentration of radioactivity in each scan was obtained as an area-weighted sum of the concentration of each slice and adjusted to a nominal value of 50 mL/min/100 g. The data underwent transformation into a common anatomical space and was smoothed with a three-dimensional gaussian filter to 16 mm full width at half maximum. The study design involved a comparison of regional blood flow during traumatic vs. neutral conditions in PTSD and comparison subject groups examined separately, and the interaction between group (PTSD vs. comparison subjects) and condition (combat vs. neutral presentations) with global blood flow considered as a confounding covariate. Statistical analyses yielded image data sets in which the values assigned to individual voxels correspond to *t* statistic (Friston et al 1991). Statistical images were displayed with values of *Z* score units. A threshold *Z* score of 3.00 ($p < .001$) was used to examine areas of activation within hypothesized areas. Location of areas of activation were identified as the distance from the anterior commissure in mm, with *x*-, *y*-, and *z*-coordinates, using a standard stereotaxic atlas (Talairach and Tournoux 1988).

Behavioral (PASS, PTSD, CADSS, SUDs, and analog rating

Table 1. Psychophysiological and Behavioral Ratings in PTSD Patients and Comparison Subjects

	PTSD patients (n = 10)										Comparison subjects (n = 10)										Time × diagnosis int.-F
	Baseline		Neutral-1		Neutral-2		Combat-1		Combat-2		Baseline		Neutral-1		Neutral-2		Combat-1		Combat-2		
	Mean	SD	Mean	SD	Mean	SD	Mean	SD	Mean	SD	Mean	SD	Mean	SD	Mean	SD	Mean	SD	Mean	SD	
Systolic BP	130.9	9.5	135.4	17.1	130.2	9.1	133.5	7.3	137.1	11.8	128.5	12.1	133.1	16.2	131.4	16.3	129.0	11.5	131.3	14.1	0.2
Diastolic BP	78.8	5.6	80.3	7.4	80.6	6.3	84.6	8.0	86.0	6.8	77.5	5.1	79.0	4.9	80.3	6.0	80.1	6.8	79.2	7.9	0.86 ^a
Pulse	69.0	15.6	68.6	13.2	65.4	12.0	66.3	11.3	66.6	12.0	67.9	11.8	67.1	10.0	66.0	10.0	65.2	8.1	66.2	9.3	0.0
CADSS	1.9	2.6	3.6	4.3	7.5	7.7	7.1	8.8	12.3	12.1	1.8	4.1	3.9	6.6	1.4	2.8	1.9	3.2	1.0	1.9	2.94 ^{a,b}
PASS	28.8	2.1	29.4	2.2	32.7	5.9	35.5	8.3	41.8	13.7	27.4	1.0	28.6	3.4	27.4	0.7	27.2	0.6	27.6	1.6	4.78 ^{b,c}
PTSD Scale	15.3	1.1	16.5	2.5	19.5	7.3	25.5	6.5	32.5	7.7	14.0	0.0	14.1	0.3	14.1	0.3	14.5	1.3	14.2	0.6	15.1
Fear analogue	0.05	0.11	0.05	0.10	0.03	0.08	0.15	0.17	0.26	0.24	0.00	0.00	0.00	0.00	0.00	0.00	0.00	0.00	0.00	0.0	4.33
SUDs	13.0	12.0	11.0	11.0	15.0	17.0	33.0	16.0	42.0	28.0	1.0	3.0	4.0	13.0	3.0	8.0	3.0	8.0	0.0	0.0	5.58

CADSS, Clinician Administered Dissociative States Scale; PASS, Panic Attack Symptom Scale; SUDs, Subjective Units of Distress scale.

^aSignificant main effect for diagnosis ($p < .05$).

^bSignificant time by diagnosis interaction ($p < .05$).

^cDuncan’s multiple range test showed significant increase during combat slides relative to neutral slides and baseline in the PTSD patients ($p < .05$).

scores) and psychophysiological (heart rate and blood pressure) measures were compared between PTSD and comparison subject groups using repeated-measures analysis of variance (ANOVA) with time as the repeated measure. When there was a significant main effect for time, Duncan’s multiple range test was performed to determine what time points showed significant differences from the baseline measures.

Results

Repeated-measures ANOVA for diastolic blood pressure (DBP) demonstrated a significant main effect for diagnosis, with higher DBP in PTSD relative to comparison subjects (Table 1), but not a significant main effect for time ($F = 1.63$; $p = .17$). PTSD patients had relatively greater increases with traumatic slides than comparison subjects (significant time by diagnosis effect), for PTSD, anxiety, and dissociative symptoms, as well as subjective distress and fear (Table 1).

Combat veterans with PTSD had increased blood flow with traumatic pictures and sounds in cerebellum, right inferior frontal gyrus, and midbrain. Combat veterans without PTSD had increased blood flow in cerebellum,

right anterior cingulate, left visual association cortex, left middle frontal gyrus, and right middle temporal gyrus (Z score > 3.00 ; $p < .001$) (Table 2). Exposure to traumatic pictures and sound in combat veterans with PTSD resulted in decreased blood flow in bilateral medial prefrontal cortex (subcallosal gyrus, or Brodmann’s area 25), adjacent areas of left anterior cingulate, left thalamus, left visual association cortex, and superior temporal and left middle temporal cortex. In combat veterans without PTSD, traumatic pictures and sounds were associated with decreased blood flow in left superior temporal cortex, left precentral (motor) cortex, left inferior parietal lobule, midcingulate, cerebellum, and right lingual gyrus (Z score > 3.00 ; $p < .001$) (Table 3).

There was a significant difference in pattern of cerebral blood flow response to traumatic pictures and sounds between veterans with and without PTSD (i.e., significant interaction between condition and PTSD diagnosis) in left inferior parietal lobule, posterior cingulate (area 23), left inferior motor cortex (precentral gyrus), right lingual gyrus, and an area that included dorsal pons and lateral cerebellum, but also portions of parahippocampal gyrus (Z score > 3.00 ;

Table 2. Areas of Increased Blood Flow with Combat-Related Slides and Sounds Relative to Neutral Slides and Sounds in PTSD Patients and Comparison Subjects

Z score	PTSD (n = 10)				Z score	Comparison subjects (n = 10)			
	Talairach coordinates					Talairach coordinates			
	x	y	z	Brain region		x	y	z	Brain region
4.89	24	-82	-28	R. cerebellum	5.25	-34	-78	-24	L. cerebellum
4.53	12	-92	-20		4.23	4	-82	-16	R. cerebellum
4.24	2	-80	-12		4.11	-10	-86	-8	L. visual association cortex (18)
3.62	50	28	0	R. interior frontal (47)	3.75	-30	12	28	L. middle frontal (9)
3.58	52	20	4		3.67	12	38	20	R. anterior cingulate (32)
3.27	12	-30	-8	R. midbrain	3.27	44	-66	12	R. middle temporal gyrus (39)

Z score > 3.00 , $p < .001$.

Table 3. Areas of Decreased Blood Flow with Combat-Related Slides and Sounds Relative to Neutral Slides and Sounds in PTSD Patients and Comparison Subjects

PTSD patients (n = 10)					Comparison subjects (n = 10)				
Z score	Talairach coordinates			Brain region	Z score	Talairach coordinates			Brain region
	x	y	z			x	y	z	
5.04	-50	-10	0	L. superior temporal pole (22)	5.80	-58	-32	20	L. superior temporal gyrus (41)
4.88	-10	-22	12	L. Thalamus	5.66	-52	-6	8	L. precentral (6)
4.42	-36	-32	12	L. superior temporal (41)	5.09	-50	0	24	
4.59	8	20	-12	R. Mesofrontal (25)	4.77	-46	-4	24	
4.36	-8	18	-12	L. Mesofrontal (25)	4.14	-40	-28	28	L. inferior parietal lobule (40)
4.23	-34	-86	16	L. visual area (19)	4.13	56	-6	8	R. superior temporal pole (22)
3.60	-22	-90	20		3.06	62	-34	8	
3.98	-8	52	0	L. anterior cingulate (32)	3.61	2	-12	32	Posterior cingulate (23)
3.87	50	-4	0	R. superior temporal gyrus (21)	3.53	12	-54	-4	R. cerebellum
3.66	-56	-32	-4	L. middle temporal gyrus (21)	3.09	18	-50	-12	
					3.05	8	-56	0	R. posterior parahippocampus (lingual) (19)

Z score > 3.00, p < .001.

p < .001) (Table 4, Figures 1 and 2). The significant interaction was related to a pattern of increase in PTSD and decrease in non-PTSD, or the combination of the two. In general the PTSD patients showed a tendency to increase blood flow, whereas control subjects showed a significant decrease in blood flow (Table 3), in these areas. The exact percentage of change in these areas in PTSD and non-PTSD groups is shown in Figure 1. In the area of dorsal pons/cerebellum/parahippocampal gyrus PTSD patients showed an increase in blood flow, whereas in non-PTSD veterans there was a decrease in blood flow.

There were also significant differences in pattern of cerebral blood flow response to traumatic pictures and sounds between veterans with and without PTSD (i.e., significant interaction between condition and PTSD diagnosis) in bilateral medial prefrontal cortex (subcallosal gyrus; Brodmann's area 25), and bilateral middle temporal gyrus, primarily due to deactivation in the PTSD patients

(Z score > 3.00; p < .001) (Table 4, Figures 1 and 3). The area of significant difference in medial prefrontal cortex was immediately adjacent to and in fact merged into anterior cingulate (area 24 and 32). In this area differences between groups were due to activation in non-PTSD (but not PTSD) veterans.

Discussion

Vietnam veterans with combat-related PTSD compared to combat veterans without PTSD showed significant differences in cerebral blood flow response to traumatic pictures and sounds in cortical and subcortical regions involved in memory, visuospatial processing, and emotion that are hypothesized to play a role in the generation of symptoms of PTSD. PTSD patients (but not non-PTSD veterans) demonstrated a decrease in blood flow in medial prefrontal cortex (subcallosal gyrus; Brodmann's area 25) and mid-

Table 4. Areas of Significant Interaction between Condition (Combat Slides and Sounds versus Neutral Slides and Sounds) and PTSD Diagnosis in Vietnam Combat Veterans with and without PTSD

Areas with Patterns of Increased Blood Flow in PTSD and Decreased Blood Flow in non-PTSD ^a					Areas with Patterns of Increased Blood Flow in non-PTSD and Decreased Blood Flow in PTSD ^b				
Z score	Talairach coordinates			Brain region	Z score	Talairach coordinates			Brain region
	x	y	z			x	y	z	
3.36	-40	-28	28	L. inferior parietal Louule (40)	4.12	8	20	-12	Medial prefrontal (subcallosal gyrus) (25)
3.22	8	-56	0	R. lingual gyrus (parahippocampus) (19)	3.32	-8	18	-12	
3.17	8	-40	-20	R. cerebellum/pons/parahippocampus	3.24	44	-66	12	R. middle temporal gyrus (39)
3.17	2	-12	32	Mid cingulate (23)	3.23	-56	-32	-4	L. middle temporal gyrus (21)
3.00	-46	-4	24	L. precentral gyrus (motor cortex) (6)	2.99	-12	-22	12	L. thalamus

Z score > 3.00; p < .001.

^aSignificance of interaction term could be related to either increases in PTSD or decreases in non-PTSD, or a combination of the two.

^bSignificance of interaction term could be related to either increases in non-PTSD or decreases in PTSD, or a combination of the two (see Figure 1).

Other areas of interaction significant at the p < .01 level included: (greater increase in PTSD) cerebellum (Z score = 2.64; x = -20, y = -66, z = -28), (greater decrease in non-PTSD) right superior temporal gyrus (Z score = 2.54; x = 60, y = -34, z = 12), (greater increase in non-PTSD) right anterior cingulate (Z score 2.83; x = 12, y = 44, z = 12), (greater increase in non-PTSD) left visual association cortex (19) (Z score 2.37; x = -30, y = -88, z = 16).

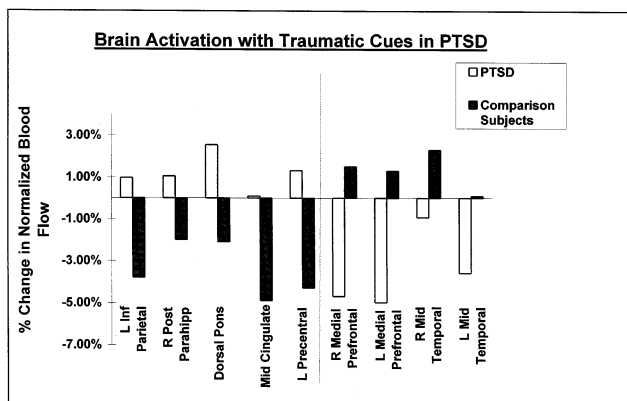


Figure 1. Percent change in globally normalized regional cerebral blood flow with exposure to traumatic cues (combat slides and sounds) relative to the neutral condition (neutral slides and sounds) in Vietnam combat veterans with PTSD and comparison subjects, showing regions in which there were significant group by condition interactions ($p < .001$).

dle temporal gyrus. The area of deactivation in medial prefrontal cortex was immediately adjacent to an area of right anterior cingulate (areas 24 and 32) in which there was greater activation in the non-PTSD control subjects. There were also significant differences in posterior cingulate (area 23), inferior parietal cortex, lingual gyrus, and left precentral gyrus (motor cortex). Differences in pattern of activation in these areas were primarily related to significant decreases in non-PTSD subjects, although there was a tendency to increase in PTSD patients.

The area of medial prefrontal cortex (subcallosal gyrus, or Brodmann's area 25) implicated in this study is adjacent

and inferior to anterior cingulate (Brodmann's areas 24 and 32) and superior to posterior orbitofrontal cortex. This area plays an important role in emotion, social behavior, and endocrine and autonomic responses to stress (Sesack et al 1989; Vogt et al 1992; Morgan et al 1993; Carmichael and Price 1994, 1995; Damasio et al 1994; Morgan and LeDoux 1995; Devinsky et al 1995; George et al 1995). Recent studies have also shown decreased function in this part of the medial prefrontal cortex in patients with depression (Drevets et al 1997), suggesting correlates with pathological emotional states in other psychiatric disorders. Lesions in this area in animals resulted in a failure of extinction to fear responding (Morgan et al 1993) (although see Gewirtz et al 1997). This finding may be secondary to a release of inhibitory inputs to the amygdala, which plays a critical role in conditioned fear responding (Davis 1992; LeDoux 1993). A failure of extinction to fear is an important component of the clinical presentation of patients with PTSD, which we have hypothesized to be secondary to a failure of medial frontal cortex inhibition of the amygdala (Bremner et al 1995a); however, it should be noted that according to our model, one might predict greater activation of amygdala in PTSD, which unlike prior PTSD studies (Rauch et al 1996; Shin et al 1997) was not found in the current study.

This area merged into another portion of anterior cingulate (area 24 and 32) in which differences in blood flow were primarily related to greater activation in non-PTSD subjects compared to PTSD. This portion of anterior cingulate is functionally connected with area 25 and is involved in emotion, evaluation of stimulus/response, and

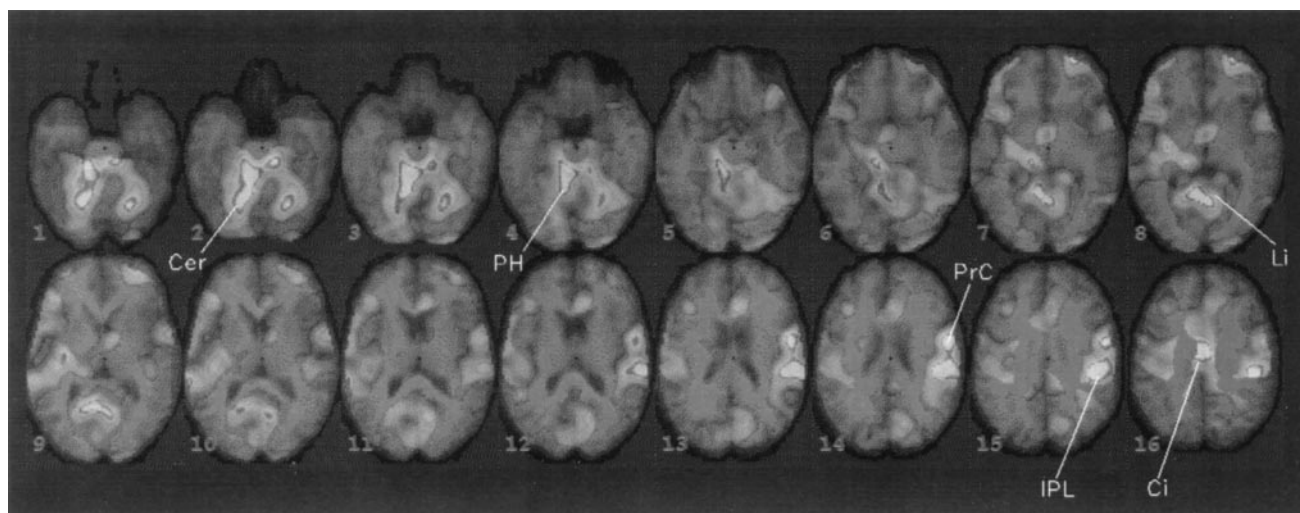


Figure 2. Statistical parametric map of areas of significant interaction between PTSD diagnosis and condition. Areas of white and gray represent regions in which there were significant interactions between condition (traumatic versus neutral) and group (PTSD versus comparison subjects) (Z score > 3.00 ; $p < .001$). Statistical significance is related to patterns of increased blood flow in PTSD, decreased blood flow in non-PTSD, or some combination of the two. Cer, cerebellum; PH, parahippocampal gyrus; Li, lingual gyrus; PrC, precentral gyrus; IPL, inferior parietal lobule; Ci, posterior cingulate.

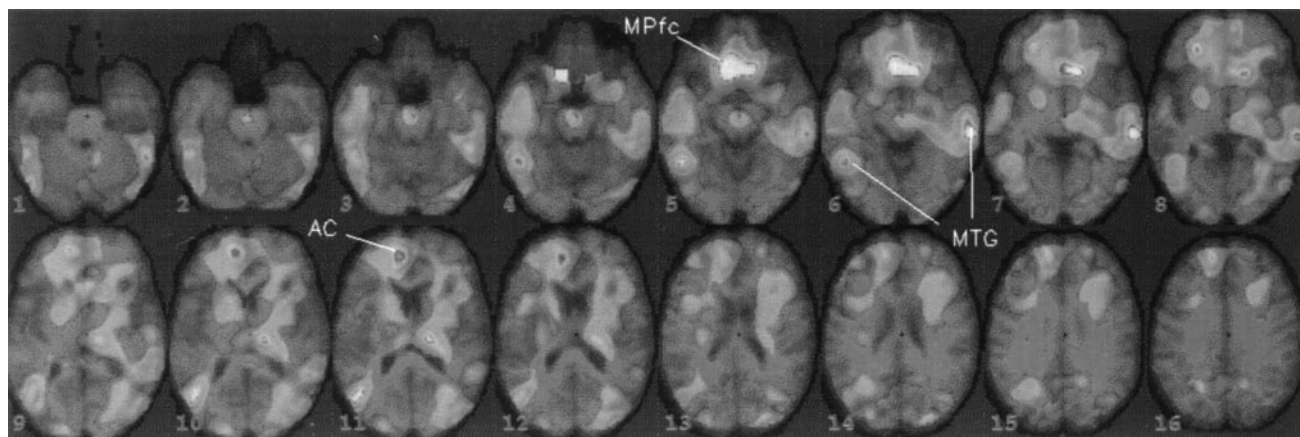


Figure 3. Statistical parametric map overlaid on a magnetic resonance image template of areas of significant interaction between PTSD diagnosis and condition. Areas of white and gray represent regions in which there were significant interactions between condition (traumatic versus neutral) and group (PTSD versus comparison subjects) (Z score > 3.00 ; $p < .001$). Statistical significance is related to deactivation in the area of medial prefrontal gyrus (area 25) (large white area in frontal cortex) and bilateral middle temporal cortex. Several slices above the large medial frontal deactivation is a smaller area of significant difference in the area of right anterior cingulate (image's right is patient's right), which is secondary to activation seen in non-PTSD (but not PTSD). AC, anterior cingulate (area 24 and 32); MPfc, medial prefrontal cortex (area 25); MTG, middle temporal gyrus.

selection for action (Vogt et al 1992; Devinsky et al 1995). Rauch et al (1996) found anterior cingulate activation with traumatic scripts in a sample of PTSD patients. This study did not involve a comparison, however, with normal control subjects, which is significant since anterior cingulate activation is a well-replicated finding in normal subjects as demonstrated with a number of paradigms for induction of emotional states (George et al 1993, 1994, 1995; Benkelfat et al 1995; Lane et al 1997; Reiman et al 1997). Emerging data from several groups are showing activation in anterior cingulate with traumatic scripts or sounds in normal subjects that are equal to or greater than those seen in PTSD (L. Shin, personal communication, 11/23/97; I. Liberzon, personal communication, 11/23/97; Rauch et al 1997). The data therefore suggest that anterior cingulate activation is a "normal" brain response to traumatic stimuli, and that a relative failure of activation is characteristic of PTSD. Lesions of anterior cingulate in rats resulted in an increase in fearfulness (Morgan and LeDoux 1995). One might speculate that hypofunction of this area is related to the increased fearfulness seen in PTSD. Decreased function in anterior cingulate (area 24) was also found in patients with depression (Mayberg et al 1997) and schizophrenia (Andreasen et al 1992; Taminga et al 1992).

The current study differed from other published studies of PTSD in not finding activation of gyrus rectus and medial orbitofrontal cortex (Rauch et al 1996; Shin et al 1997); however, in our prior study of PTSD symptom induction with the noradrenergic agent, yohimbine, we found a failure of activation in orbitofrontal cortex/gyrus rectus in PTSD, whereas healthy control subjects showed

a robust increase in metabolism in this area. In addition, we found a pattern of lower orbitofrontal metabolism being associated with greater panic anxiety in the PTSD patients (Bremner et al 1997a). We also did not find deactivation of left inferior gyrus, unlike prior studies (Rauch et al 1996; Shin et al 1997). Differences in findings between studies may be related to multiple factors including study population and paradigms for symptom induction (Mayberg et al 1997). Prior studies that found inferior frontal gyrus deactivation (but not the current study) included tasks requiring encoding and processing of verbal material, a function that is mediated by this region. The current study was consistent with previous investigations (Rauch et al 1996; Bremner et al 1997a; Shin et al 1997) in finding a decrease in middle temporal gyrus blood flow during PTSD symptom provocation. The middle temporal cortex (in addition to medial prefrontal cortex) plays a role in the extinction of fear through inhibition of amygdala function (Jarrell et al 1987; Romanski and LeDoux 1993). Decreased middle temporal gyrus blood flow has also been consistently seen in PET studies of functional correlates of verbal declarative memory tasks (Tulving et al 1994).

Exposure to combat-related slides and sounds resulted in differences in blood flow in several subcortical and cortical areas involved in memory and visuospatial processing. These included lingual gyrus, an adjacent area that included a portion of lateral cerebellum merging with dorsal pons and parahippocampal gyrus (note this was added after display of spm on magnetic resonance template), posterior cingulate (area 23), and inferior parietal lobule. The lingual gyrus has been implicated in visual

memory and memory for faces (Kapur et al 1995). Parahippocampal gyrus is adjacent to lingual gyrus and has also been implicated in emotion and anxiety (Nordahl et al 1990; Reiman et al 1984, 1986) as well as symptoms of PTSD (Rauch et al 1996; Shin et al 1997). Visuospatial processing [mediated by the inferior parietal cortex (Jonides et al 1993; Pardo et al 1991; Posner et al 1988; Petersen et al 1988) and posterior cingulate (area 23) (Vogt et al 1992; Devinsky et al 1995)] is an important component of preparation for coping with a physical threat. We have hypothesized the involvement of these areas in the neuroanatomical network mediating symptoms of PTSD (Bremner et al 1995a). Consistent with this formulation, a recent PET study found increased blood flow in posterior cingulate during exposure to films of a bank robbery in bank tellers who were victims of a bank robbery (Fischer et al 1996).

Areas not hypothesized to show a difference between PTSD and control subjects included motor cortex, although this area was previously implicated in PTSD by Rauch et al (1996) and has been consistently shown to activate in studies of declarative memory. This area may carry motor aspects of memory necessary for the organism's preparation for action during the stress response (Squire and Zola-Morgan 1991; Lang et al 1983). PTSD patients showed greater activation in a portion of lateral cerebellum, although a strong cerebellar activation was seen in both veterans with and those without PTSD. Recent PET studies have established a role for the cerebellum in attention and memory, probably mediated by its projections through the thalamus to prefrontal cortex (Ashkoomoff and Courchesne 1992; Leiner 1989). The area of greater activation in PTSD in lateral cerebellum merged with a portion of the dorsal pons, a major site of noradrenergic neurons in the brain that have projections throughout cortical and several subcortical regions. This system plays a critical role in stress and coping with threat (Abercrombie and Jacobs 1987; Aston-Jones et al 1991; Rasmussen et al 1986; reviewed in Bremner et al 1996b, 1996c). Our own PET findings showing differences in metabolic response to yohimbine challenge in PTSD are consistent with increased central noradrenergic responsivity in PTSD (Bremner et al 1997a).

Findings in the current study are best interpreted as secondary to disturbances of a functional network of interrelated brain areas that mediate memory, visuospatial processing, and the emotional valence of stimuli. Motor cortex (area 6), anterior (area 24) and posterior cingulate (area 23), lingual gyrus, visual association cortex (19), superior temporal cortex, and thalamus all have projections to both lateral prefrontal and parietal cortex (Selemon and Goldman-Rakic 1988). The area of posterior cingulate (area 23) implicated in this study has functional

connections with hippocampus and adjacent cortex (parahippocampal gyrus) [which led to its original classification as part of the "limbic brain" (Gray 1982)] as well as parietal cortex. These areas (posterior cingulate, parahippocampal gyrus, and parietal cortex, all of which are implicated in the current study) may act in concert to mediate cognitive functions of visuospatial processing and memory that are necessary for coping with threat (Vogt et al 1992). PTSD may represent a dysfunction in the brain's response to coping with stress and potential threat, which involves excessive recruitment in brain areas responsible for visuospatial processing, attention, and memory, in addition to attaching an affective valence to stimuli. According to this model the symptoms of PTSD are related to an abnormality in a functional network involving multiple cortical and subcortical regions, rather than one or two areas that specifically are responsible for the mediation of "emotion."

In the current study we included only combat veterans who met specific inclusion criteria based on reactivity to traumatic stimuli, therefore the results are not generalizable to PTSD patients without psychophysiological responsiveness. Although PTSD patients were included with a heart rate response to traumatic pictures and sounds of greater than 5 bpm, there was not a robust measured response during the actual scan. Heart rate and blood pressure were measured at the end of the stimulus presentation period. This may have limited our ability to detect significant increases. Although there was a robust behavioral effect, changes in SUDs ratings (as well as physiological responses) were not as great as those previously reported with traumatic scripts. We used a fixed order of presentation of stimuli, to avoid contamination of the control condition by traumatic slides; however, this protocol could lead to order effects. Other possible limitations are related to the pictures and sounds selected for this study. Brain activation may be related to factors related to the control condition (e.g., feelings of pleasantness during the neutral condition). This is avoided, however, by statistical analyses examining the interaction between diagnosis and condition, on which the primary conclusions of the study are based. The use of pictures and sounds as presentation materials also has inherent strengths, in that they are similar to stimuli encountered in daily life, and they can be standardized and validated as provocative material, and presented in an identical fashion to all subjects involved in a study protocol. Measurements of respiration or $p\text{CO}_2$ were not performed to examine the possibility that PTSD patients hyperventilated to a greater degree than non-PTSD patients, resulting in changes in $p\text{CO}_2$ and blood flow; however, it was not our observation that PTSD patients hyperventilated during the study (as, for instance, patients with panic disorder might be ex-

pected to do). In any case pCO_2 would be expected to have a global effect on blood flow, and the data analysis performed involved a correction for variations in global blood flow.

In summary, the current study showed that exposure to traumatic slides and sounds in PTSD subjects (but not non-PTSD subjects) resulted in a decrease in blood flow in medial prefrontal cortex (subcallosal gyrus; Brodmann's area 25) and middle temporal gyrus, and a failure in activation in immediately adjacent right anterior cingulate (areas 24 and 32). There were also differences (primarily related to significant decreases in non-PTSD subjects) in posterior cingulate (area 23), inferior parietal cortex, lingual gyrus, and left precentral gyrus (motor cortex).

Several functional neuroimaging studies have now been performed in patients with PTSD. Studies to date are consistent in implicating medial prefrontal cortex, including anterior cingulate, in the pathophysiology of PTSD. In spite of the clear role for the amygdala in conditioned fear responses in animals, there is some question whether the amygdala is involved in PTSD symptoms; however, differences in study populations and study paradigms make it difficult to interpret the findings from different studies. The most important next step in the field would be to establish similar study populations and a standard paradigm for symptom induction study across sites, to establish with some degree of confidence neuroanatomical correlates for the symptomatology of PTSD.

This study was supported by a Veterans Administration Career Development Award to Dr. Bremner, and a National Center for Posttraumatic Stress Disorder grant.

We would like to thank Eric Anderson for expert assistance in image processing and analysis, Susan Insall, RNMSW, for assistance in data management, Chin Ng, PhD, and Holley Dey, MD, for assistance with PET instrumentation and methodology, and Dayton Rich, CNMT, for assistance in PET image acquisition.

References

- Abercrombie ED, Jacobs BL (1987): Single-unit response of noradrenergic neurons in the locus coeruleus of freely moving cats. I. Acutely presented stressful and nonstressful stimuli. *J Neurosci* 7:2837–2843.
- Andreasen NC, Rezai K, Alliger R, Swayze VW II, Flaum M, Kirchner P, et al (1992): Hypofrontality in neuroleptic naïve patients and in patients with chronic schizophrenia. Assessment with Xenon 133 single photon emission computed tomography and the Tower of London. *Arch Gen Psychiatry* 49:943–958.
- Ashkoomoff NA, Courchesne E (1992): A new role for the cerebellum in cognitive operations. *Behav Neurosci* 106:731–738.
- Aston-Jones G, Chiang C, Alexinsky T (1991): Discharge of noradrenergic locus coeruleus neurons in behaving rats and monkeys suggests a role in vigilance. In: Barnes CD, Pompeiano, editors. *Progress in Brain Research*. New York: Elsevier Science Publications, pp. 501–519.
- Benkelfat C, Bradwejn J, Meyer E, Ellenbogen M, Milot S, Gjedde A, et al (1995): Functional neuroanatomy of CCK sub 4-induced anxiety in normal healthy volunteers. *Am J Psychiatry* 152:1180–1184.
- Blanchard EB, Kielb LC, Pallmeyer TP, Gerardi RJ (1982): A psychophysiological study of posttraumatic stress disorder in Vietnam combat veterans. *Psychiatr Q* 54:220–229.
- Bremner JD, Krystal JH, Southwick SM, Charney DS (1995a): Functional neuroanatomical correlates of the effects of stress on memory. *J Trauma Stress* 8:527–554.
- Bremner JD, Randall PR, Scott TM, Bronen RA, Delaney RC, Seibyl JP, et al (1995b): MRI-based measurement of hippocampal volume in posttraumatic stress disorder. *Am J Psychiatry* 152:973–981.
- Bremner JD, Krystal JH, Charney DS, Southwick SM (1996a): Neural mechanisms in dissociative amnesia for childhood abuse: Relevance to the current controversy surrounding the False Memory Syndrome. *Am J Psychiatry* 153:FS71–FS82.
- Bremner JD, Krystal JH, Southwick SM, Charney DS (1996b): Noradrenergic mechanisms in stress and anxiety: I. Preclinical studies. *Synapse* 23:28–38.
- Bremner JD, Krystal JH, Southwick SM, Charney DS (1996c): Noradrenergic mechanisms in stress and anxiety: II. Clinical studies. *Synapse* 23:39–51.
- Bremner JD, Innis RB, Ng CK, Staib L, Duncan J, Bronen R, et al (1997a): PET measurement of central metabolic correlates of yohimbine administration in posttraumatic stress disorder. *Arch Gen Psychiatry* 54:246–256.
- Bremner JD, Randall P, Vermetten E, Staib L, Bronen RA, Mazure CM, et al (1997b): MRI-based measurement of hippocampal volume in posttraumatic stress disorder related to childhood physical and sexual abuse: A preliminary report. *Biol Psychiatry* 41:23–32.
- Bremner JD, Krystal JH, Putnam F, Southwick SM, Marmar C, Charney DS, et al (1998): Measurement of dissociative states with the Clinician Administered Dissociative States Scale (CADSS). *J Trauma Stress* 11:125–136.
- Carmichael ST, Price JL (1994): Architectonic subdivision of the orbital and medial prefrontal cortex in the macaque monkey. *J Comp Neurol* 346:366–402.
- Carmichael ST, Price JL (1995): Limbic connections of the orbital and medial prefrontal cortex in macaque monkeys. *J Comp Neurol* 363:615–641.
- Damasio H, Grabowski T, Frank R, Galaburda AM, Damasio AR (1994): The return of Phineas Gage: Clues about the brain from the skull of a famous patient. *Science* 264:1102–1105.
- Davis M (1992): The role of the amygdala in fear and anxiety. *Annu Rev Neurosci* 15:353–375.
- Devinsky O, Morrell MJ, Vogt BA (1995): Contributions of anterior cingulate to behavior. *Brain* 118:279–306.
- Drevets WC, Price JL, Simpson JR Jr, Todd RD, Reich T, Vannier M, et al (1997): Subgenual prefrontal cortex abnormalities in mood disorders. *Nature* 386:824–827.
- Fischer H, Wik G, Fredrikson M (1996): Functional neuroanatomy of robbery re-experience: Affective memories studied with PET. *Neuroreport* 7:2081–2086.

- Friston K, Frith C, Liddle P, Frackowiak R (1991): Comparing functional (PET) images: The assessment of significant change. *J Cereb Blood Flow Metab* 11:690–699.
- George MS, Ketter TA, Gill DS, Haxby JV, Ungerleider LG, Herscovitch P, et al (1993): Brain regions involved in recognizing facial emotion or identity: An oxygen-15 PET study. *J Neuropsychiatry Clin Neurosci* 5:384–394.
- George MS, Ketter TA, Parekh PI, Rosinsky N, Ring H, Casey BJ, et al (1994): Regional brain activity when selecting a response despite interference: An H²15 O PET study of the stroop and an emotional stroop. *Hum Brain Mapping* 1:94–209.
- George MS, Ketter TA, Parekh PI, Horwitz B, Herscovitch P, Post RM (1995): Brain activity during transient sadness and happiness in healthy women. *Am J Psychiatry* 152:341–351.
- Gewirtz JC, Falls WA, Davis M (1997): Normal conditioned inhibition and extinction of freezing and fear-potentiated startle following electrolytic lesions of medial prefrontal cortex. *Behav Neurosci* 111:712–726.
- Goldensohn E (1992): Structural lesions of the frontal lobe: Manifestations, classification, and prognosis. In: Chauvel P, Delgado-Escueta AV, et al, editors. *Advances in Neurology*. New York: Raven Press.
- Gray JA (1982): *The Neuropsychology of Anxiety*. New York: Oxford University Press.
- Gurvits TG, Shenton MR, Hokama H, Ohta H, Lasko NB, Gilbertson MW, et al (1996): Magnetic resonance imaging study of hippocampal volume in chronic combat-related posttraumatic stress disorder. *Biol Psychiatry* 40:192–199.
- Jarrell TW, Gentile CG, Romanski LM, McCabe PM, Schneiderman N (1987): Involvement of cortical and thalamic auditory regions in retention of differential bradycardiac conditioning to acoustic conditioned stimuli in rabbits. *Brain Res* 412:285–294.
- Jonides J, Smith EE, Koeppe RA, Awh E, Minoshima S, Mintun MA (1993): Spatial working memory in humans as revealed by PET. *Nature* 363:623–625.
- Kaloupek DG, Bremner JD (1996): Psychophysiological measures and methods in trauma research. In: Carlson EB, editor. *Trauma Research Methodology*. Lutherville, MD: Sidran Press, pp. 82–104.
- Kapur N, Friston KJ, Young A, Frith CD, Frackowiak RSJ (1995): Activation of human hippocampal formation during memory for faces: A PET study. *Cortex* 31:99–108.
- Lane RD, Reiman EM, Ahern GL, Schwartz GE, Davidson RJ (1997): Neuroanatomical correlates of happiness, sadness, and disgust. *Am J Psychiatry* 154:926–933.
- Lang PJ (1983): Cognition in emotion: Concept and action. In: Izard CE, Kagan J, Zajonc R, editors. *Emotions, Cognition and Behavior*. New York: Cambridge University Press.
- Lang PJ, Levin DN, Miller GA, Kozak MJ (1983): Fear behavior, fear imagery, and the psychophysiology of emotion: The problem of affective response integration. *J Abnorm Psychol* 92:276–306.
- LeDoux JL (1993): Emotional memory: In search of systems and synapses. *Ann NY Acad Sci* 149–157.
- Leiner HC (1989): Reappraising the cerebellum: What does the hindbrain contribute to the forebrain? *Behav Neurosci* 103: 998–1008.
- MacLean PD (1949): Psychosomatic disease and the visceral brain. Recent developments bearing on the Papez Theory of Emotion. *Psychosom Med* 11:338–353.
- Malloy PF, Fairbank JA, Keane TM (1983): Validation of a multimethod assessment of posttraumatic stress disorders in Vietnam veterans. *J Consult Clin Psychol* 51:488–494.
- Mayberg HS, Brannan SK, Mahurin RK, Jerabek PA, Brickman JS, Tekell JL, et al (1997): Cingulate function in depression: A potential predictor of treatment response. *Neuroreport* 8:1057–1061.
- McEwen BS, Gould EA, Sakai RR (1992): The vulnerability of the hippocampus to protective and destructive effects of glucocorticoids in relation to stress. *Br J Psychiatry* 160:18–24.
- Morgan MA, LeDoux JE (1995): Differential contribution of dorsal and ventral medial prefrontal cortex to the acquisition and extinction of conditioned fear in rats. *Behav Neurosci* 109:681–688.
- Morgan MA, Romanski LM, LeDoux JE (1993): Extinction of emotional learning: Contribution of medial prefrontal cortex. *Neurosci Letters* 163:109–113.
- Nordahl TE, Semple WE, Gross M, Mellman TA, Stein MB, Goyer P, et al (1990): Cerebral glucose metabolic differences in patients with panic disorder. *Neuropsychopharmacology* 3:261–271.
- Pardo JV, Pardo PJ, Janer KW, Raichle ME (1990): The anterior cingulate cortex mediates processing selection in the Stroop attentional conflict paradigm. *Proc Natl Acad Sci USA* 87:256–259.
- Pardo JV, Fox PT, Raichle ME (1991): Localization of a human system for sustained attention by positron emission tomography. *Nature* 349:61–64.
- Petersen SE, Fox PT, Posner MI, Mintun M, Raichle ME (1988): Positron emission tomographic studies of the cortical anatomy of single-word processing. *Nature* 331:585–589.
- Pitman RK (1989): Posttraumatic stress disorder, hormones, and memory [editorial]. *Biol Psychiatry* 26:221–223.
- Pitman RK, Orr SP, Foa DF, de Jong JB, Claiborn JM (1987): Psychophysiological assessment of posttraumatic stress disorder imagery in Vietnam combat veterans. *Arch Gen Psychiatry* 44:970–975.
- Posner MI, Petersen SE, Fox PT, Raichle ME (1988): Localization of cognitive operations in the human brain. *Science* 240:1627–1631.
- Prins A, Kaloupek DG, Keane TM (1995): Psychophysiological evidence for autonomic arousal and startle in traumatized adult populations. In: Friedman MJ, Charney DS, Deutch AY, editors. *Neurobiological and Clinical Consequences of Stress: From Normal Adaptation to PTSD*. New York: Raven Press, pp. 291–314.
- Rasmussen K, Morilak DA, Jacobs BL (1986): Single-unit activity of locus coeruleus neurons in the freely moving cat. I. During naturalistic behaviors and in response to simple and complex stimuli. *Brain Res* 371:324–330.
- Rauch SL, van der Kolk BA, Fisler RE, Alpert NM, Orr SP, Savage CR, et al (1996): A symptom provocation study of posttraumatic stress disorder using positron emission tomography and script driven imagery. *Arch Gen Psychiatry* 53: 380–387.

- Rauch SL, Savage CR, Alpert NM, Fischman AJ, Jenike MA (1997): The functional neuroanatomy of anxiety: A study of three disorders using positron emission tomography and symptom provocation. *Biol Psychiatry* 42:446–452.
- Reiman EM, Raichle ME, Butler FK, Herscovitch P, Robins E (1984): A focal brain abnormality in panic disorder: A severe form of anxiety. *Nature* 310:683–685.
- Reiman EM, Raichle ME, Robins E, Mintun MA, Fusselman MJ, Fox PT, et al (1986): The application of positron emission tomography to the study of panic disorder. *Am J Psychiatry* 143:469–477.
- Reiman EM, Lane RD, Ahern GL, Schwartz GE, Davidson RJ, Friston KJ, et al (1997): Neuroanatomical correlates of externally and internally generated human emotion. *Am J Psychiatry* 154:918–925.
- Romanski LM, LeDoux JE (1993): Information cascade from primary auditory cortex to the amygdala: Corticocortical and corticoamygdaloid projections of temporal cortex in the rat. *Cereb Cortex* 3:515–532.
- Semple WE, Goyer PF, McCormick R, Compton-Toth B, Morris E, Donovan B, et al (1996): Attention and regional cerebral blood flow in posttraumatic stress disorder patients with substance abuse histories. *Psychiatry Res* 67:17–28.
- Sesack SR, Deutch AY, Roth RH, Bunney BS (1989): Topographic organization of the efferent projections of the medial prefrontal cortex in the rat: An anterograde tract-tracing study using *Phaseolus vulgaris* leucoagglutinin. *J Comp Neurol* 290:213–242.
- Shin LM, Kosslyn SM, McNally RJ, Alpert NM, Thompson WL, Rauch SL, et al (1997): Visual imagery and perception in posttraumatic stress disorder: A positron emission tomographic investigation. *Arch Gen Psychiatry* 54:233–237.
- Southwick SM, Krystal JH, Morgan CA, Johnson D, Nagy LM, Nicolaou A, et al (1993): Abnormal noradrenergic function in posttraumatic stress disorder. *Arch Gen Psychiatry* 50:266–274.
- Spitzer RL, Williams JBW, Gibbon M (1987): *Structured Clinical Interview for DSM-IV*. New York: New York State Psychiatric Institute.
- Squire LR, Zola-Morgan S (1991): The medial temporal lobe memory system. *Science* 253:1380–1386.
- Stein MB, Koverola C, Hanna C, Torchia MG, McClarty B (1997): Hippocampal volume in women victimized by childhood sexual abuse. *Psychol Med* 27:951–959.
- Talairach J, Tournoux P (1988): *Co-Planar Stereotaxic Atlas of the Human Brain: 3-Dimensional Proportional System: An Approach to Cerebral Imaging*. Stuttgart-New York: Thieme-Verlag.
- Taminga CA, Thaker GK, Buchanan R, Kirkpatrick B, Alphs LD, Chase TN, et al (1992): Limbic system abnormalities identified in schizophrenia using positron emission tomography with fluorodeoxyglucose and neocortical alterations with deficit syndrome. *Arch Gen Psychiatry* 49:522–530.
- Tulving E, Kapur S, Craik FIM, Moscovitch M, Houle S (1994): Hemispheric encoding/retrieval asymmetry in episodic memory: Positron emission tomography findings. *Proc Natl Acad Sci USA* 91:2016–2020.
- Vogt BA, Finch DM, Olson CR (1992): Functional heterogeneity in cingulate cortex: The anterior executive and posterior evaluative regions. *Cereb Cortex* 2:435–443.